

# VEINES PELVIENNES de la FEMME

Profondes et superficielles

ANATOMIE

PHYSIOPATHOLOGIE

HEMODYNAMIQUE

Claude Franceschi E.mail: [claudio.franceschi@wanadoo.fr](mailto:claudio.franceschi@wanadoo.fr)

Varici  
Pelviche

=

BANALI

Patologiche solo se  
**RESPONSIBILI**

Di

Sindroma congestione pelvica

o

Varici perineali superficiali e  
arti inferiori

ELIMINARE altre cause di dolori pelivici

Dypaneuria, pesantezza, sciatica,  
pollakiuria etc...

Retroversione Uterina

Endometriosi

Nevralgia

altri

Varicocele

=

Varici

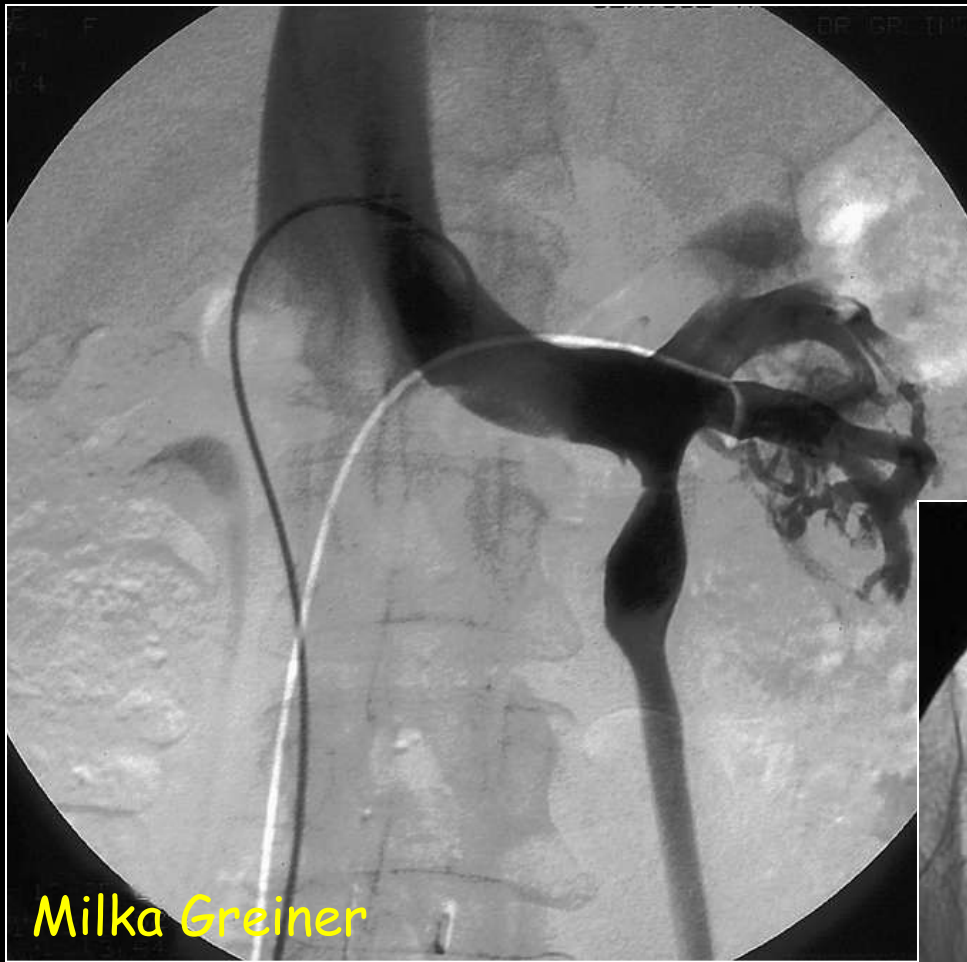
Ovariche

Typologia

dei

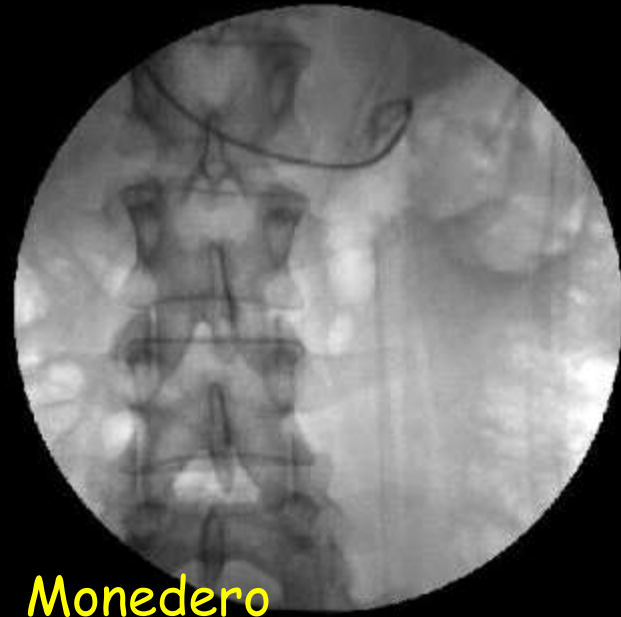varicoceli:

3 tipi

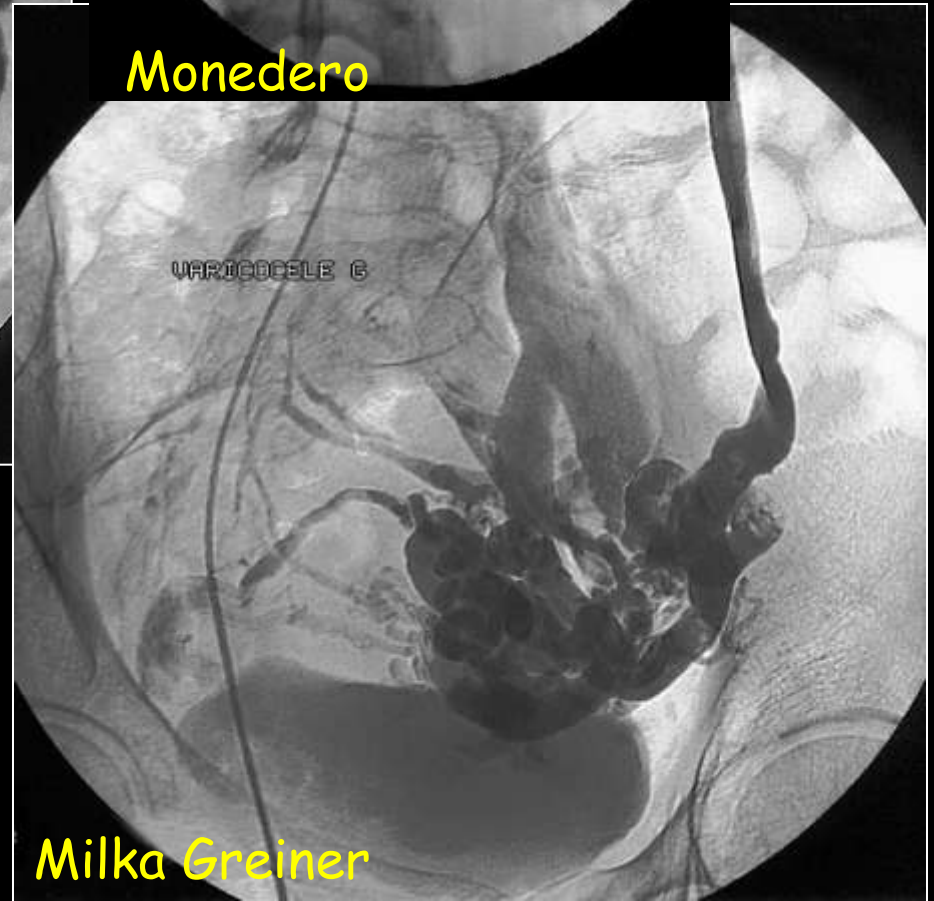


Milka Greiner

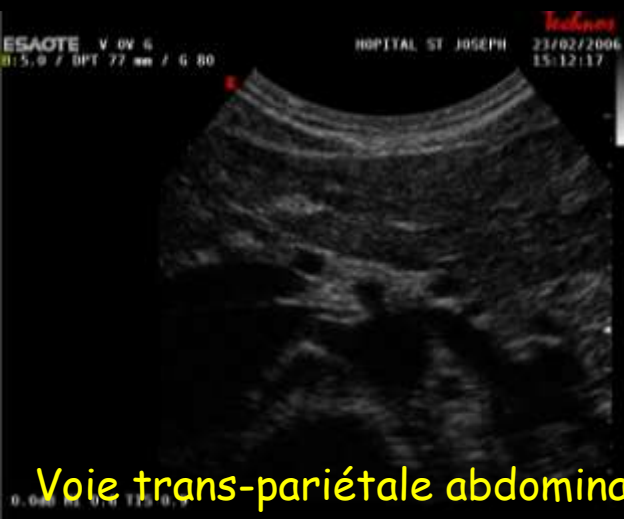
Varicocèle type 1  
Pathologie de reflux



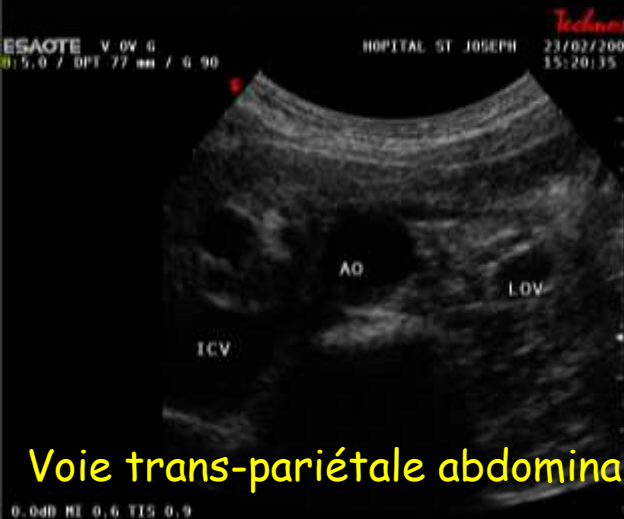
Monedero



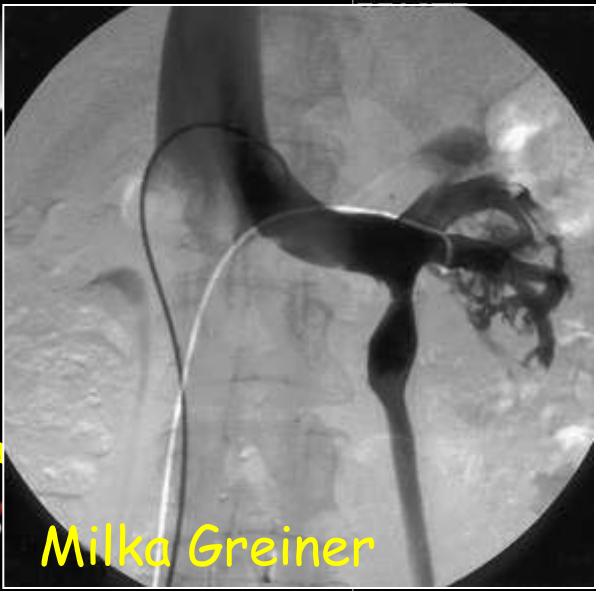
Milka Greiner



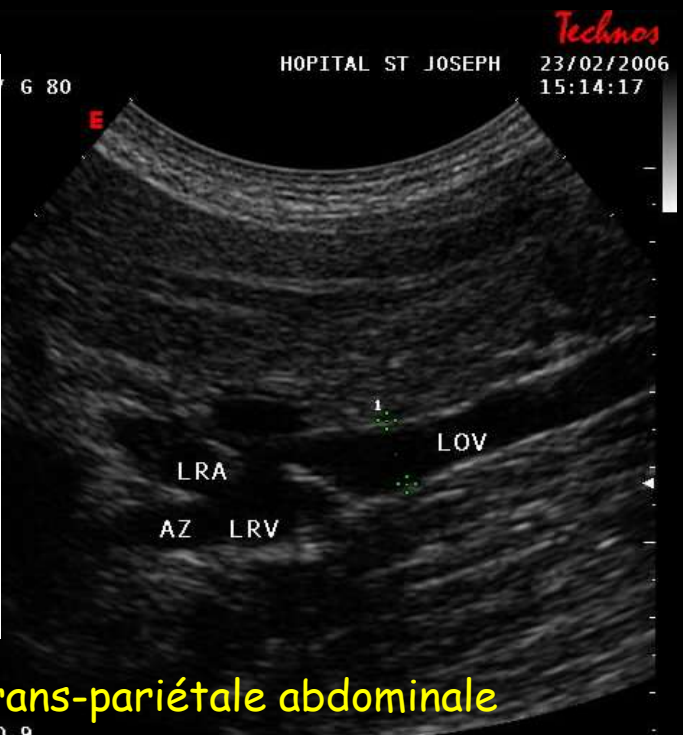
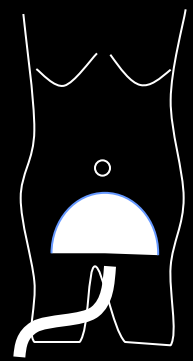
Voie trans-pariétale abdominale



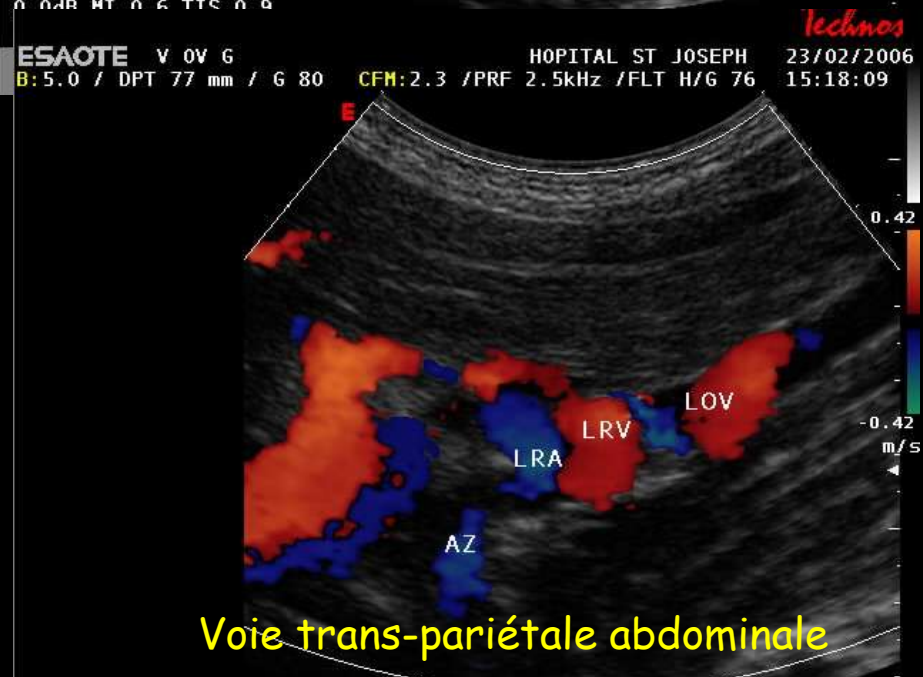
Voie trans-pariétale abdominale



Milka Greiner



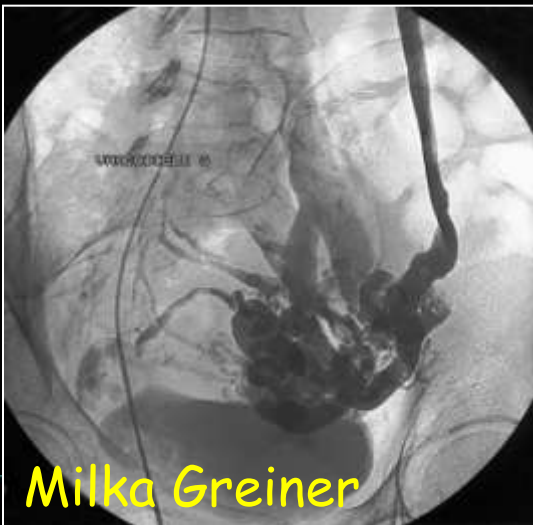Voie trans-pariétale abdominale



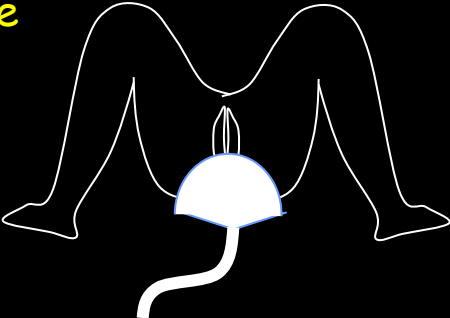
Voie trans-pariétale abdominale

Varicocèle type 1  
 Pathologie de reflux  
 Suppl. réno-azygo-lombaire

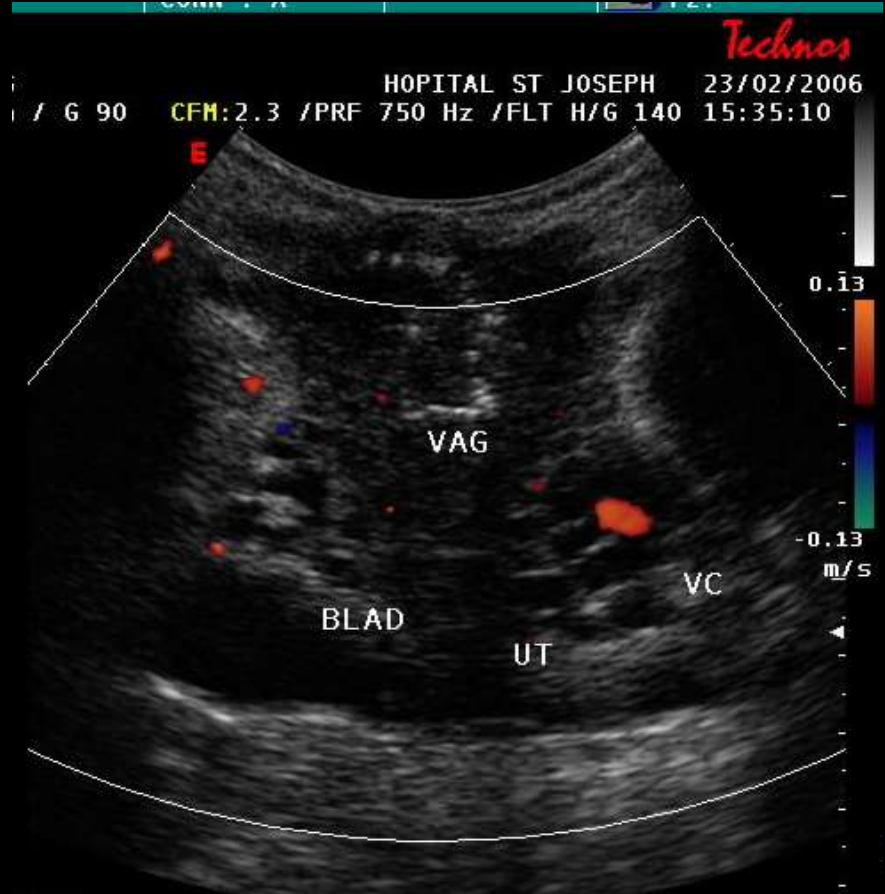
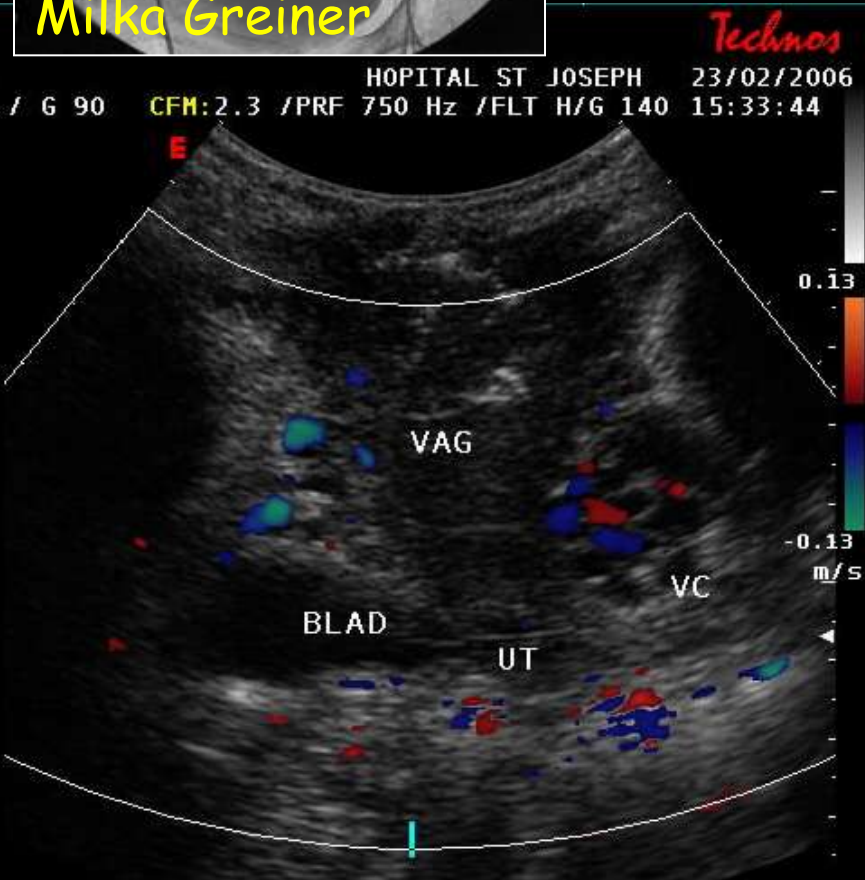


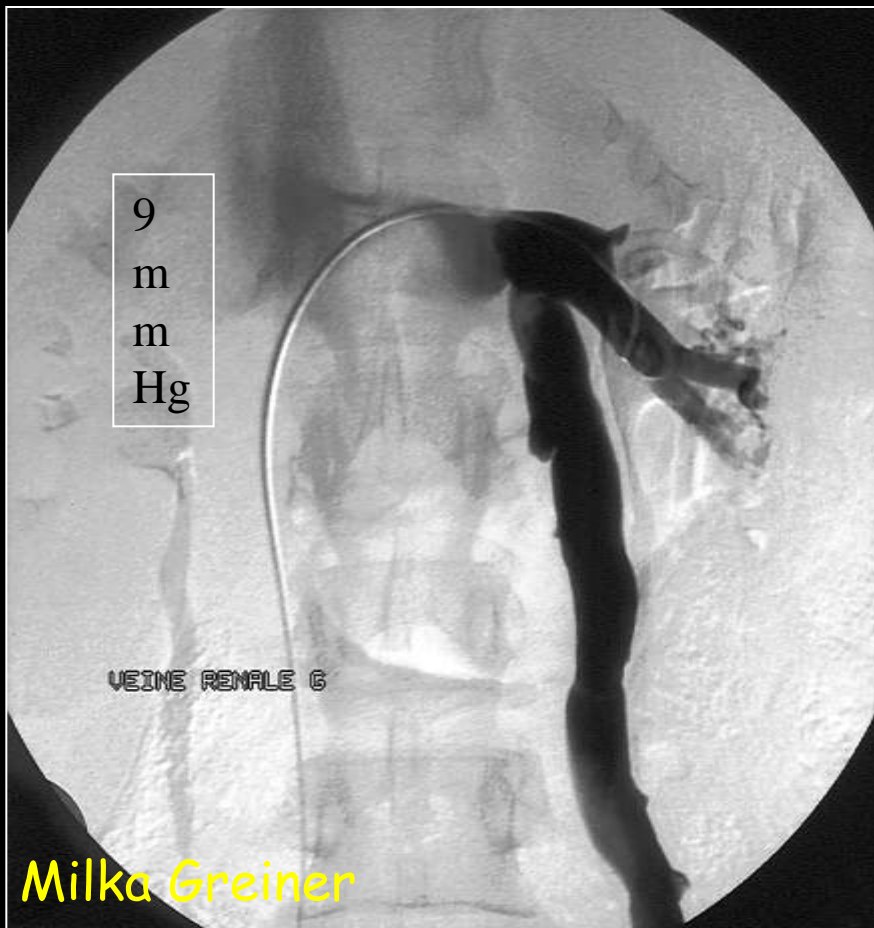

Voie trans-pariétale périnéale et non pas trans-vaginale, sonde convexe 3-5 mHz

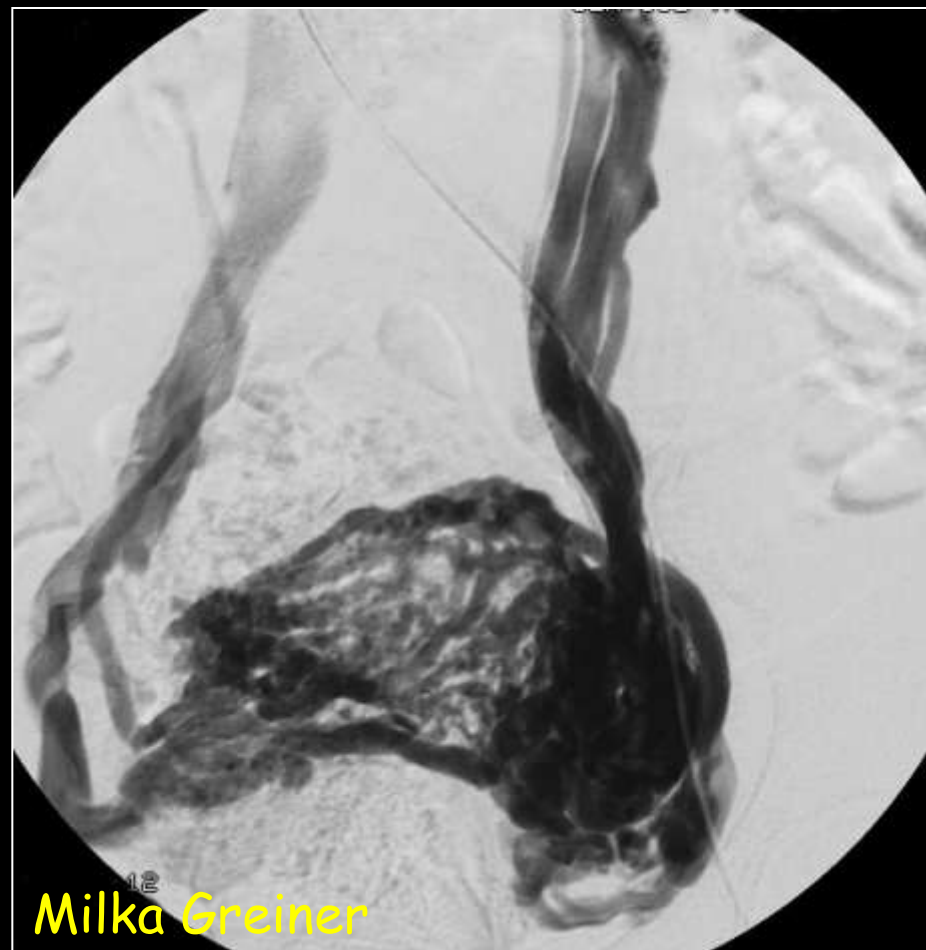


Milka Greiner

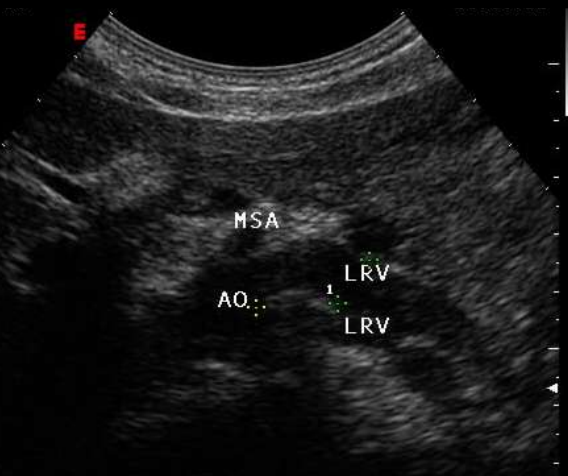




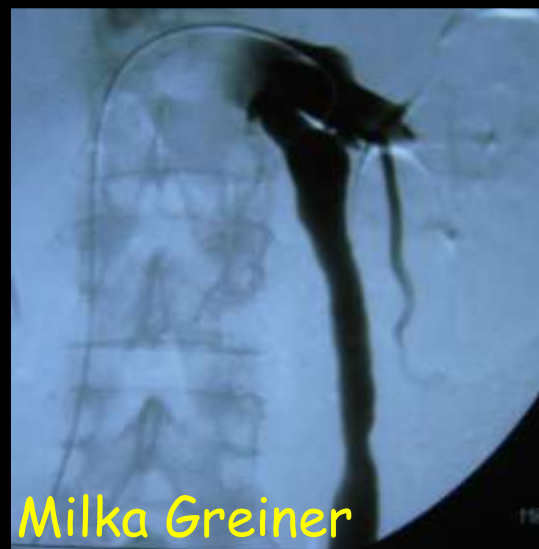Varicocèle type 2  
Anomalie du retour veineux rénal  
Gauche: Nutcracker syndrome



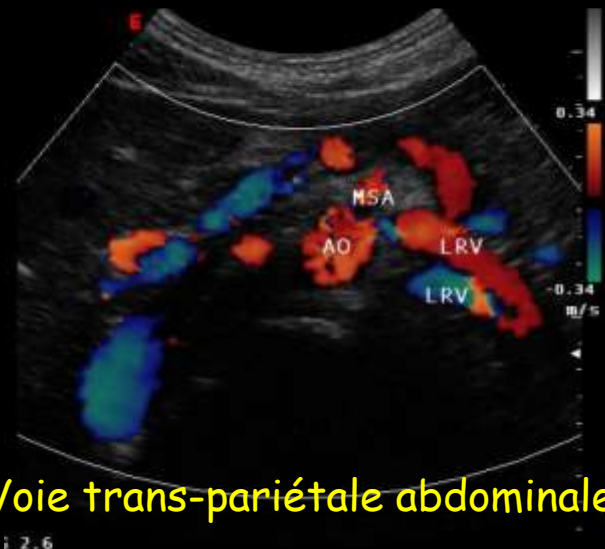
Gauche: Nutcracker Syndrome: Pince Ao-Mes totale: dérivation unique par vOvG



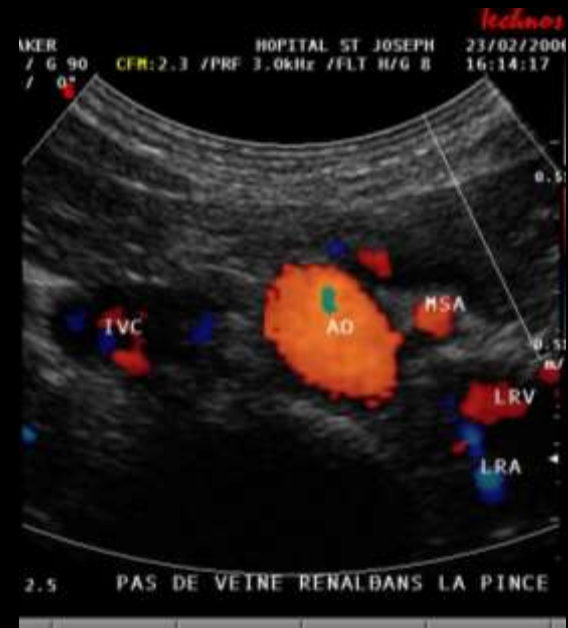
Voie trans-pariétale abdominale



Milka Greiner

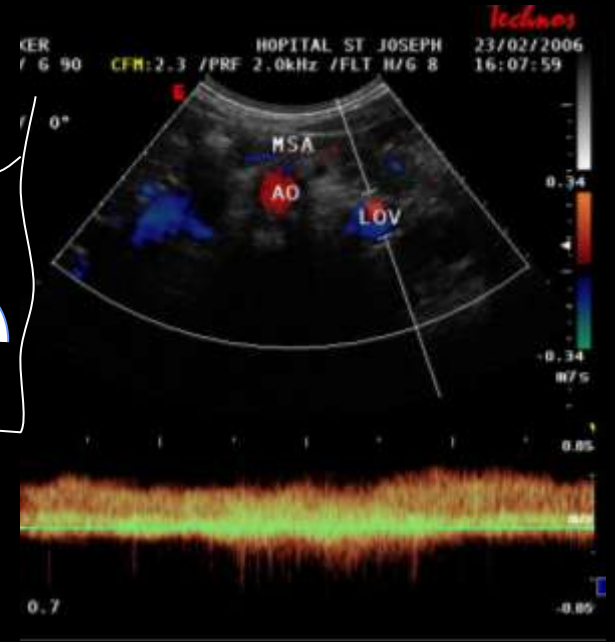
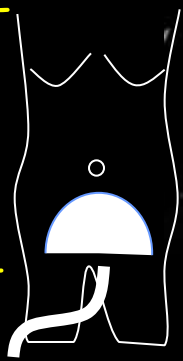


Voie trans-pariétale abdominale



Voie trans-pariétale abdominale

Flux Pince Aorto-Mesenterique  
TOALE: Flux = 0  
Pas de voie collaterale réno-azygo-lombaire  
Flux retrograde PERMANENT v.Ov.G

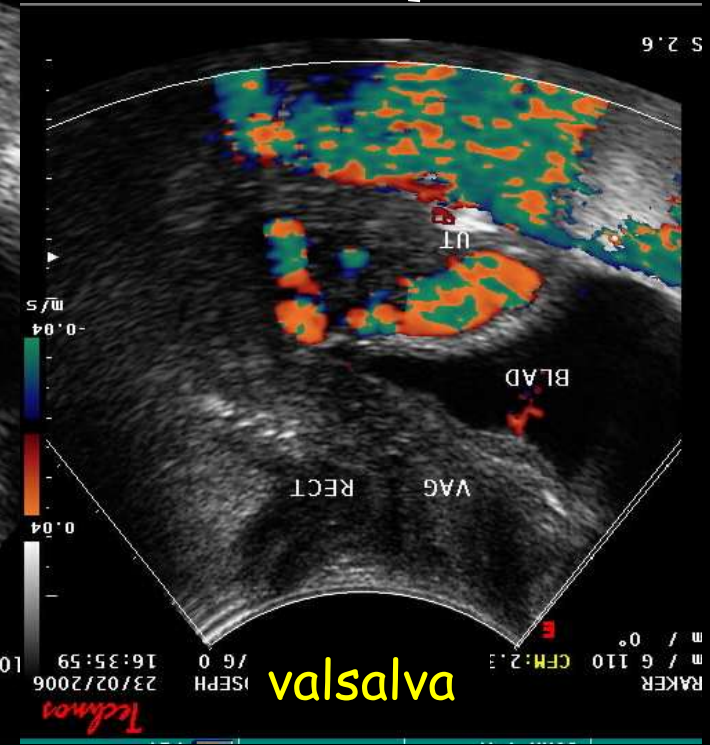
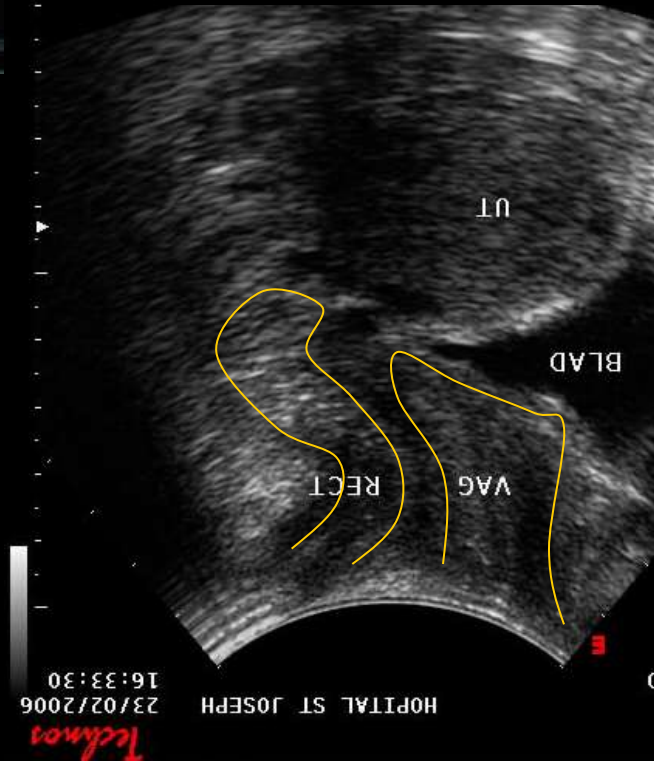
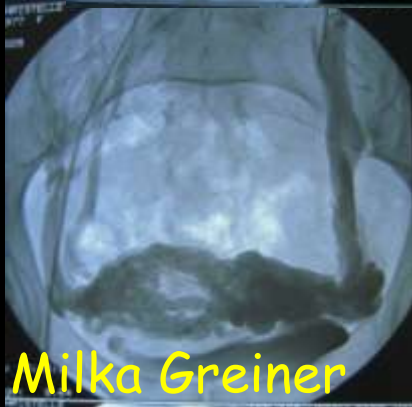
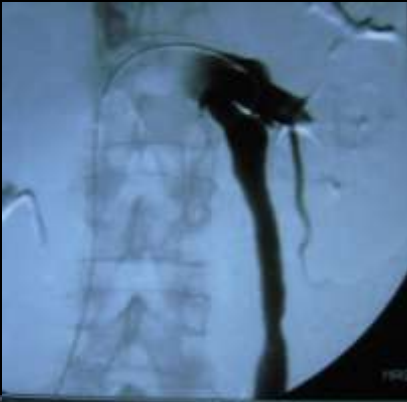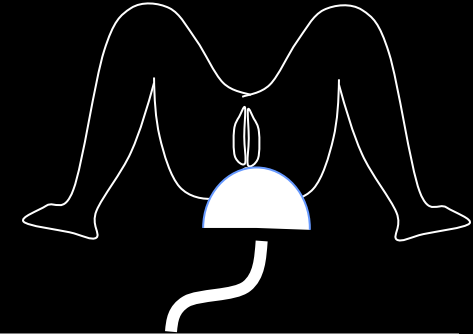


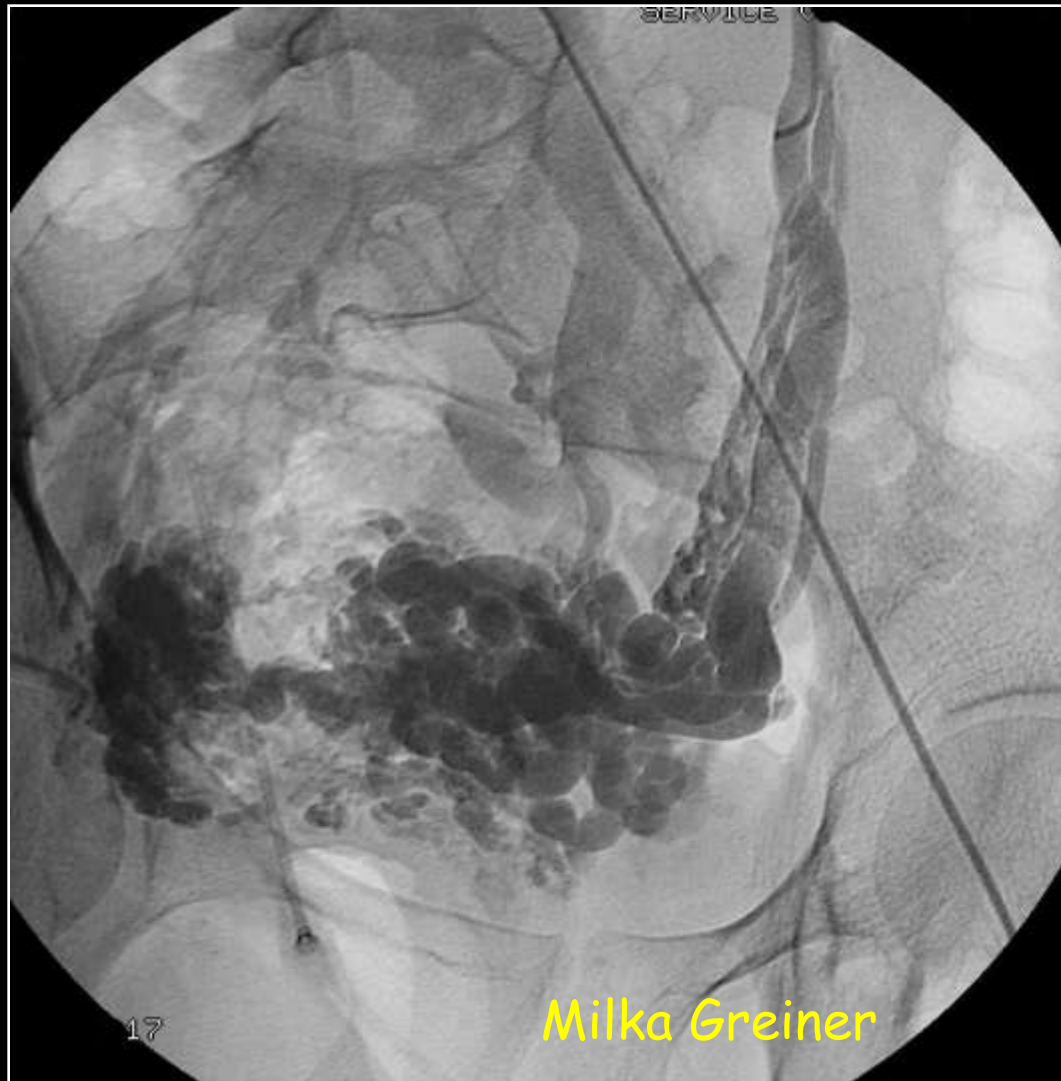Voie trans-pariétale abdominale

# Gauche: Nutcracker Syndrome: Pince Ao-Mes totale: dérivation unique par vOvG

Voie trans-pariétale périnéale et non pas trans-vaginale, sonde convexe 3-5 mHz

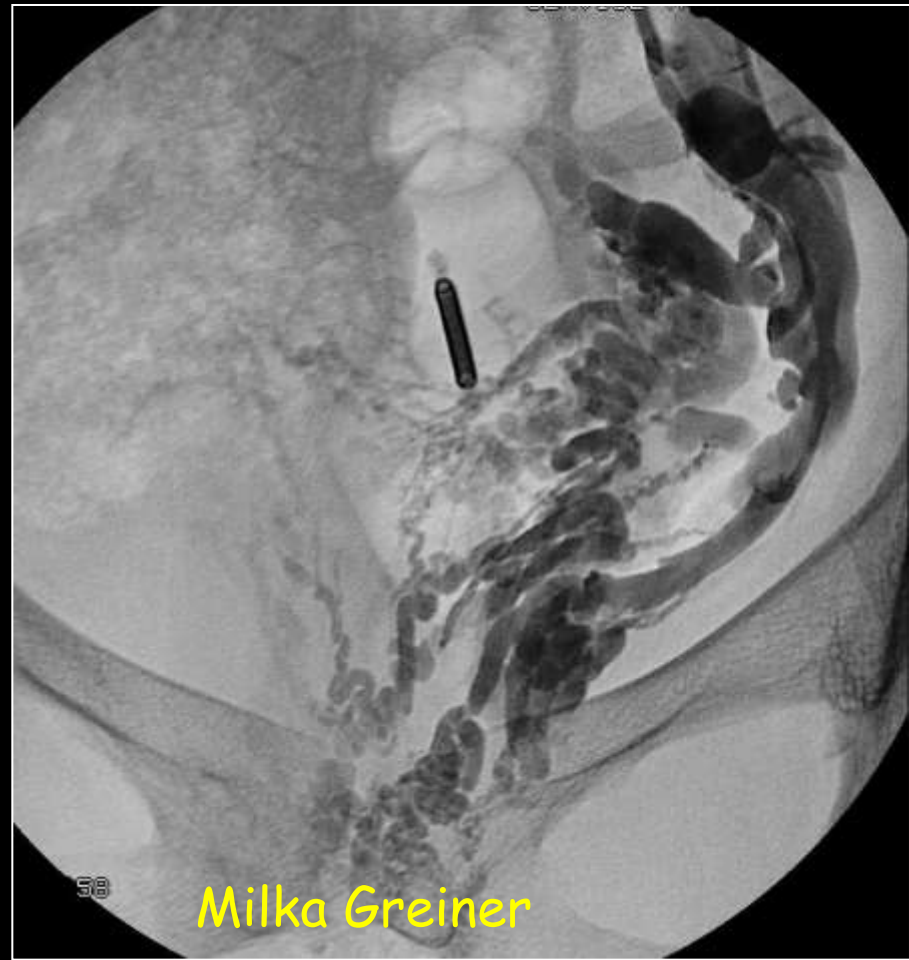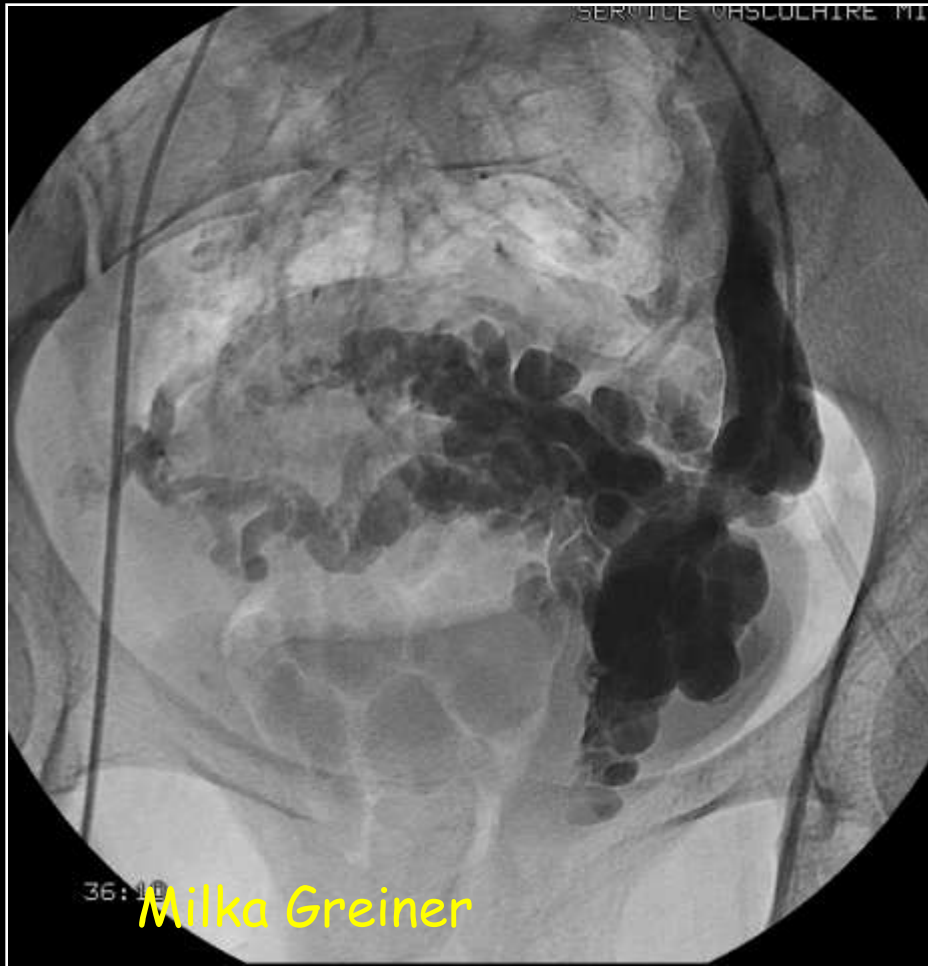
Voie trans-pariétale abdominale para-sagittale





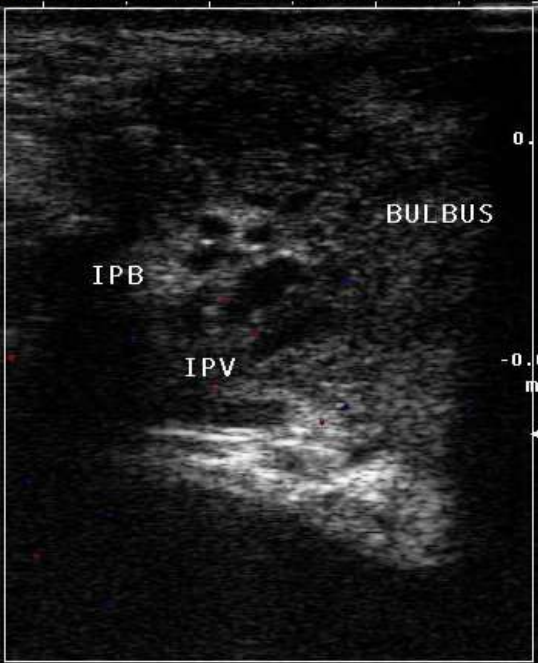
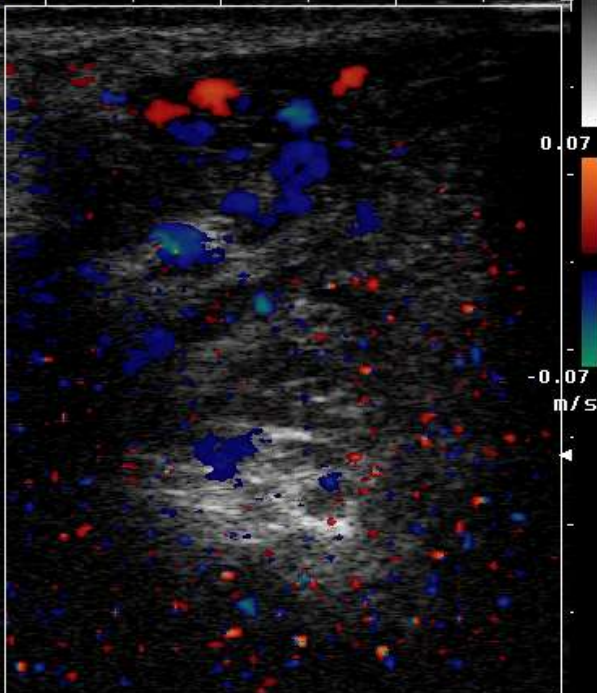
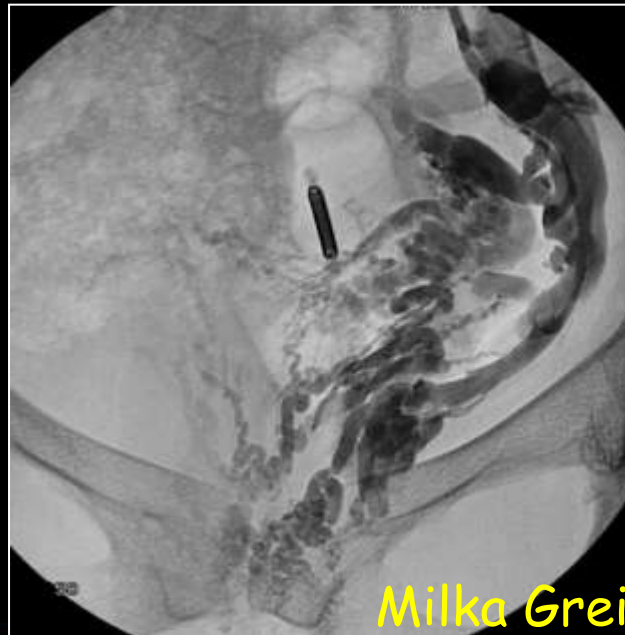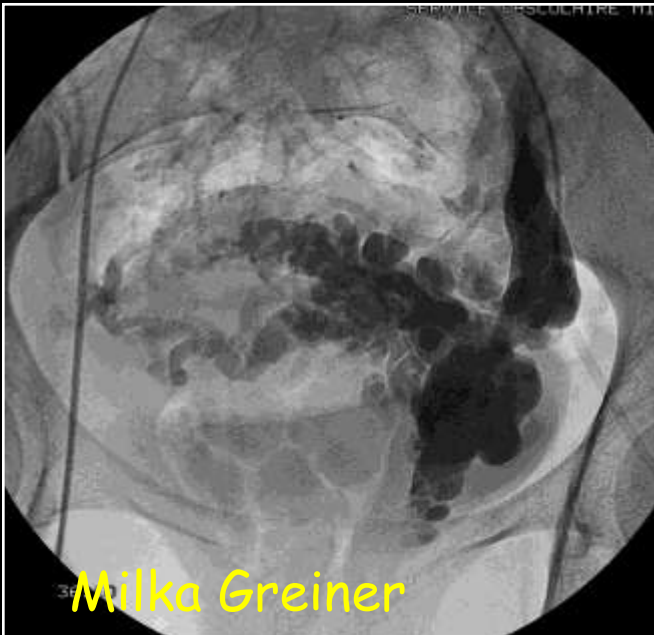Varicocèle type 3 syndrome de Masters-AlLEN  
(associé à une pathologie de reflux)

Fig 3



Syndrome de congestion pelvienne:  
varices pudendales internes

VARICI ILIACHE  
INTERNE:  
PUDENDE



Syndrome de  
congestion  
pelvienne:  
varices  
pudendales  
internes

